

Original Article



Ocular wavefront aberrations in acute central serous chorioretinopathy

Banafsheh Kharrazi Ghadimi¹, Nazli Taheri², Mohammad Reza Niyousha^{3*}

¹General Ophthalmologist, Nikookari Eye Hospital, Tabriz University of Medical Sciences, Tabriz, Iran

²Anterior Segment Service Assistant Professor, Ophthalmologist, Nikookari Eye Hospital, Tabriz University of Medical Sciences, Tabriz, Iran

³Vitoretinal Service Assistant Professor, Ophthalmologist, Nikookari Eye Hospital, Tabriz University of Medical Sciences, Tabriz, Iran

Article info

Article History:

Received: 23 Jan. 2021

Accepted: 12 March 2021

e-Published: 16 Oct. 2021

Keywords:

- Corneal Wavefront Aberration
- Macula
- Aberrometry
- Optical coherence tomography

Abstract

Introduction: Central serous chorioretinopathy (CSCR) is a condition of choroidal and retinal pathologies that may affect vision, so we assessed vision by the ocular wavefront in the acute form of CSCR.

Methods: This cross-sectional study included 21 cases (16-male, 5-female) of acute onset CSCR who were referred to the retina clinic of Nikookari Eye Hospital Visual acuity and ocular examination with and without pupillary dilation was recorded. Central macular thickness and sub-foveal fluid height of all patients were measured by spectral-domain optical coherence tomography (SD-OCT). All of the patients were analyzed by binocular visual function analyzer of Tracy Technology after complete pupillary dilation. The items such as spherical equivalent, total root mean square, total lower-order aberration, total higher-order aberration, defocus, astigmatism, secondary astigmatism, coma, spherical aberration, trefoil, Strehl ratio in point spread function, the average height in the modulation transfer function, and root mean square error registered. Generalized Estimation Equations (GEE) were used to compare two groups of affected CSCR and normal contralateral eyes.

Results: The mean uncorrected distance visual acuity in the CSCR eyes (Decimal Notation) is 0.82 ± 0.17 and in the contralateral eyes is 0.95 ± 0.09 ($P=0.002$). Analysis of macular OCT data CSCR group represents central foveal thickness of $485.9 \pm 165.12 \mu\text{m}$ and mean fluid height of $284.3 \pm 165.42 \mu\text{m}$. The mentioned optical parameters of ocular wavefront aberrations do not have significantly different results in the two groups.

Conclusion: Our study showed that CSCR reduced uncorrected visual acuity; however no significant ocular wavefront change was detected in acute CSCR.

Introduction

Central serous chorioretinopathy (CSCR) is an idiopathic condition with serous macular sensory retinal detachment from the pigmented epithelium.¹ The etiology and pathophysiology mechanisms of CSCR are not precisely discovered. It is suggested that malfunctioning of the choriocapillaris, choroidal hyper-permeability, and abnormal choroidal thickness are among its primary causes, and retinal pigment epithelium (RPE) lesions and subretinal fluid accumulation are among its secondary causes.² CSCR is more common in males between 20 and 50 years with an annual incidence rate of 9.9–10 per 100,000 in men, which is 6–7 times more frequently than in women.^{3–5} Visual acuity might be diminishing because it might induce a hyperopic shift. Vision consists of two forms of visual acuity and visual quality.⁶ Visual quality is the most influenced by optical quality.^{7,8} Optical aberrations are mentioned as the deviation of the wavefront of light.

As the light travels through the eye, it is a reason for the decreased quality of the optical system in the pathway. Ocular aberrations are divided into lower and higher-order aberrations.⁹ Adjusting corneal topography with wavefront aberrometry, the I-Trace can isolate the internal aberrations, subtracting corneal from total aberrations of the eye,⁹ some studies have investigated the role of optical aberrations on vision in retinal pathologies.^{10–12} This study aimed to assess the ocular wavefront changes in acute CSCR to find the visual quality differences between eyes. We tried to clarify subjective comprehension of visual disturbance to objective form.

Methods

This cross sectional study included Iranian patients with the acute phase of CSCR, from September to November 2019, who referred to Nikookari Ophthalmology Hospital in Tabriz University of medical science in the North-west

*Corresponding Author: Mohammad Reza Niyousha, Tel: +989143154300, Email: mreza63neusha@gmail.com

of Iran country.

Inclusion Criteria were acute onset CSCR case (patients with symptoms for less than 3-months), 20 to 50 years age, the clear media in both eyes, and healthy fellow eye.

Exclusion criteria were dry eye, amblyopia, history of previous CSCR, significant refractive error difference between the affected eye, and healthy fellow eye (more than 1 Diopter), any other ocular pathology, and past ocular surgery. All Patients enrolled to study when corrected distance visual acuity (BCVA) of both eyes was equal to 1 decimal notation.

Unilateral CSCR cases that had inclusion criteria entered the study and were compared with their healthy contralateral eye. Their ocular examination, without and with pupillary dilation, was performed. Visual acuity was checked by Snellen chart. Diagnosis of CSCR was determined by spectral-domain optical coherence tomography (SD-OCT, SPECTRALIS® Tracking Laser Tomography software version 6.0.9 Heidelberg engineering). Central macular thickness and Central sub-foveal fluid height were measured by manually adjusting outlines. Central macular thickness is the distance between the inner limiting membrane and the outer/inner segment junction, the basement membrane of RPE and Central sub-foveal fluid height is the vertical length from the innermost to the outermost of sub-foveal fluid (Figure 1).¹³

all patients had gone under binocular corneal imaging by I-Trace-visual function analyzer. (VFA TOPCON software version 1.0, Tracey Technologies, Houston, TX), after full pupillary dilation (1% Tropicamide eye drops). Then aberrometry details were obtained at a scan size of 5.0 mm, 2-4 times by an examiner.

I-trace aberrometry uses the near-infrared light, by the reflection to the level of the RPE and calculates retinal point spread function (PSF) and wavefront aberration. More details on keratometry, autorefraction, pupil diameter, topography, and wavefront aberrations were measured on the same axis.¹¹

The corneal topography was computed using Placido-disk technology. Ray tracing principles were applied

to ocular wavefront measurement.^{14,15} When patients focused on a distant target measurements were performed with dilated pupils at a fixed entrance pupil scan size of 5.0 mm.

The cardinal clinical record was uncorrected distance visual acuity (UCDVA) and BCVA. Optical parameters of this study were spherical equivalent, total root means square, total lower-order aberration, total higher-order aberrations, defocus, astigmatism, secondary astigmatism, coma, spherical aberration, trefoil, Strehl ratio in point spread function (PSF), the average height in modulation transfer function (MTF), evaluated by the same I-Trace visual function analyzer.

Sixth-order Zernike polynomial decomposition was utilizing to measure total wavefront aberrations. Root mean square (RMS) error was calculated from PSF. The Total HO is the RMS of HO terms (Z_3-Z_6); the total RMS is the RMS of all 25 Zernike terms.

The optical quality of ocular media were checked in two planes: the pupil plane and the retinal plane. Pupil plane aberration defines the ocular optical properties in individual Zernike polynomials. The image plane measures the wavefront error in the retinal plane.^{16,17}

Image quality in the image plane is divided into PSF for point objects and MTF. The Strehl ratio is a number 0 to 1. It defines as a ratio between the peak intensity of the PSF of a patient's eye, and the PSF of an ideal eye.^{16,17} The MTF is the modulus of the Fourier transform of the PSF, and the MTF of 1 describes a perfect eye¹⁶. Root mean square (RMS) error is the difference of the wavefront from an ideal plane wavefront¹⁸; and interprets wavefront error, but not directly visual performance. Different aberrations have different impacts on visual performance.¹⁹ (Figure 2)

Power and Sample Size calculator (PS power and sample size, Operating system for Windows, Version 3.1.2/August 2014, W.D. Dupont & W.D. Plummer, US) were used to calculate study samples based on Zarei-Ghanavati et al study¹². The statistical software SPSS (IBM SPSS Statistics for Windows, Version 18.0., Armonk, NY: IBM Corporation) was used for data analysis. All values were presented as mean \pm standard deviation (SD). The

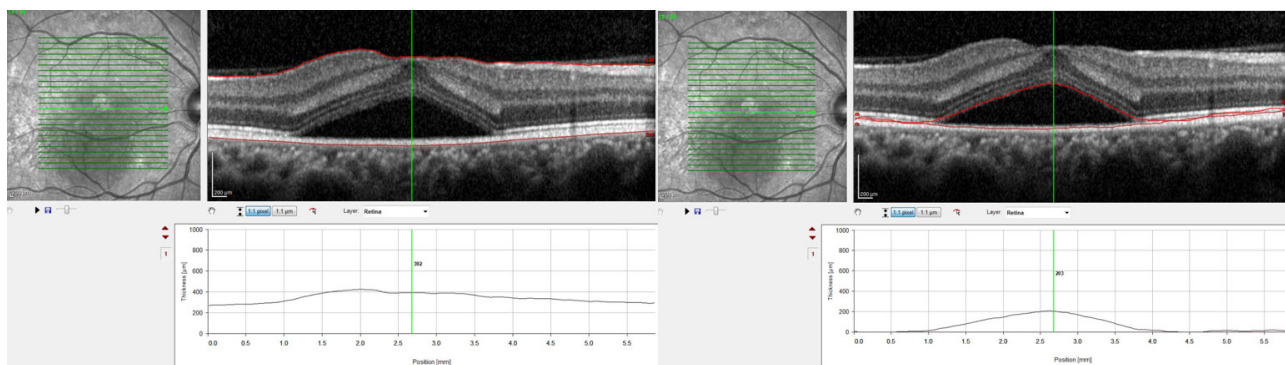


Figure 1. Central macular thickness (left) is the distance between the vitreoretinal interface and the basement membrane of RPE. Central sub-foveal fluid height (right) is the vertical length from the innermost to the outermost of sub-foveal fluid.

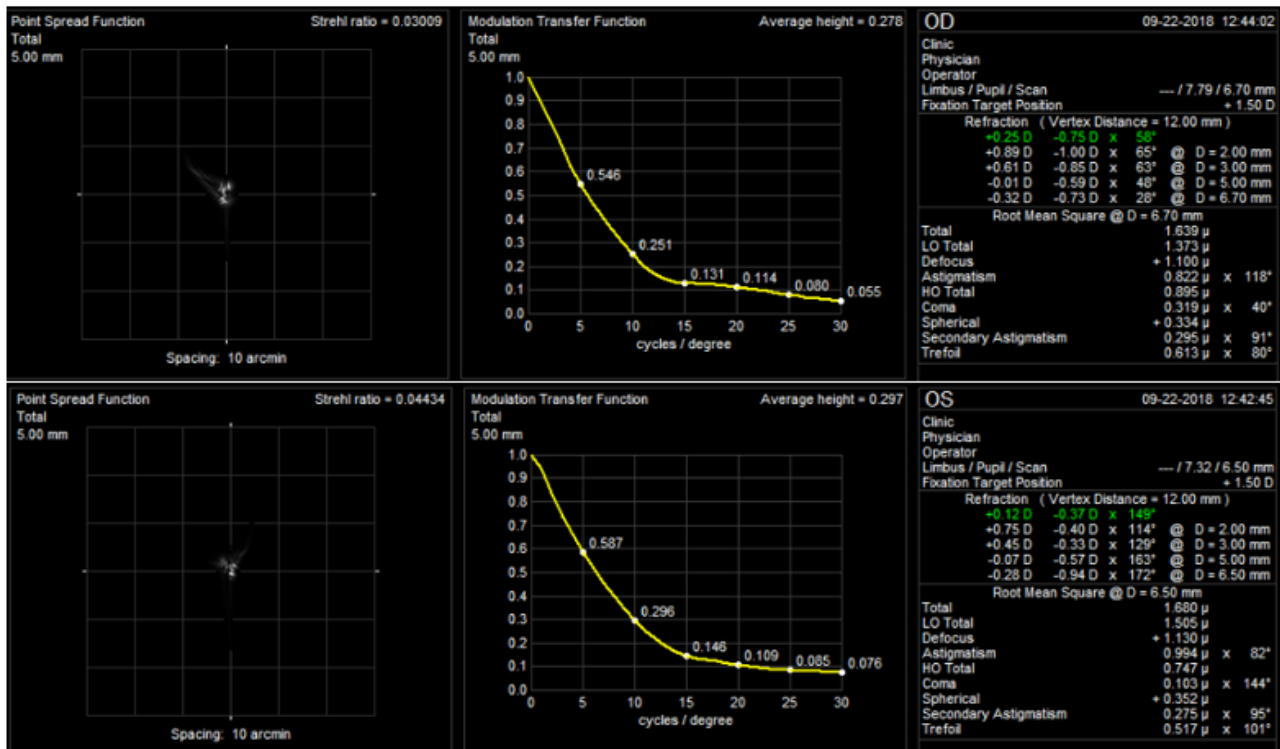


Figure 2. This image shows wavefront aberration in CSCR affected eye (upper) and healthy eye (lower) with scant central sub-foveal fluid (98 μm).

Kolmogorov-Smirnov test was used to assess the normal distribution of data. Generalized estimation equations (GEE), were used to compare means between two groups. A *P* value of 0.05 or less was considered statistically significant. (Table 1)

Results

Twenty-one patients were enrolled in this study (16-male, 5-female). The mean age of participants was 39.47 years (range 27 to 48 years). A total of 11-right and 10-left eyes with CSCR and their contralateral healthy eyes were analyzed. The mean UCDVA in the CSCR eyes and the contralateral control eyes comparison showed a significant difference (*P*=0.002). In all cases, both eyes BCVA were equal to 1 decimal notation (Table 1).

Analysis of macular OCT data of CSCR group represented macular average thickness in 1mm ETDRS circle diameter of $506.52 \pm 159.22 \mu\text{m}$, central foveal thickness of $485.9 \pm 165.12 \mu\text{m}$ and mean sub-foveal fluid height of $284.29 \pm 165.42 \mu\text{m}$.

Discussion

To improve the vision, the principal issue is to assess both visual acuity and optical quality.⁷ Some studies have shown that retinal changes affect the visual quality; which is influenced by aberration and scattering.²⁰ So it may be part of reduced vision in retinal disorders due to increased internal ocular aberration and scattering. The results of current study shows that CSCR reduces UCDVA, while a significant ocular wavefront change was not detected in

acute CSCR.

Lee et al²⁰ used the Optical Quality Analysis System (OQAS) for changes in optical quality and intraocular scattering in central serous chorioretinopathy over 3-months. They showed that MTF decreased, while objective scattering index (OSI) meaningfully increased. They could not find statistically relevant with macular thickness and optical parameters, like our study.

Bessho et al¹¹ studied 82 eyes of 66 patients with macular disease and 85 eyes of 51 patients without retinal disease. Ray-Tracing scanned wavefront at two pupil sizes up to 6th order Zernike coefficient. Third-order aberrations in the macular disease group was statistically higher than control group in phakic eyes, and it was more obvious in the larger pupil. We also evaluated CSCR patients in the large pupil and phakic eyes, and there were no meaningful results of wavefront aberrations in CSCR eyes and fellow eyes.

Mihaltz et al achieved result similar to the study by Bessho et al. In their prospective study, 33-eyes of patients with diabetic macular edema and 31-patients as a control group had been scanned by a ray-tracing wavefront device. Total and internal ocular aberrations were evaluated separately to find the source of the aberrations plan. There was a statistically significant difference between the two groups. They could not prove a statistically significant difference in Strehl ratio and HO root mean square between phakic and pseudophakic patients. The height of cystoid spaces had a significant relationship to the Strehl ratio and there was a significant relationship between the HO Strehl

Table 1. Comparison of Visual acuity, spherical equivalent and wave-front in two group

Parameters	Groups(Mean ± SD)		P value
	CSR eyes (n=21)	Fellow eyes(n=21)	
UCDVA	0.82 ± 0.17	0.95 ± 0.1	0.002*
Spherical Equivalent(3mm)	-0.4 ± 1.3	-0.37 ± 1.98	0.93
Total RMS	1.5 ± 1.92	1.83 ± 1.94	0.34
Total LO	1.38 ± 1.9	1.68 ± 1.9	0.35
Defocus	0.6 ± 2.02	0.64 ± 2.27	0.89
Astigmatism	0.78 ± 0.74	0.72 ± 0.64	0.67
Secondary Astigmatism	0.1 ± 0.1	0.1 ± 0.13	0.71
Total HO	0.5 ± 0.41	0.56 ± 0.57	0.59
Coma	0.3 ± 0.34	0.33 ± 0.42	0.73
Spherical	0.08 ± 0.2	0.15 ± 0.34	0.35
Trefoil	0.23 ± 0.2	0.25 ± 0.22	0.82
PSF (Strehl ratio) 5mm	0.04 ± 0.05	0.04 ± 0.04	0.57
MTF (average height) 5mm	0.23± 0.12	0.23 ± 0.14	0.87

UCDVA: uncorrected distance visual acuity, LO: lower order, HO: higher order, PSF: point spread function, MTF: modulation transfer function, RMS: Root mean square, *P<0.05 with significance

ratio and BCVA. In eyes with macular edema, internal HO wavefront aberrations were greater than in control eyes and visually relevant. They mentioned increased intra-retinal edema as the source of HO aberrations,¹⁰ explaining this different conclusion might be in total and internal wavefront aberrations concept, so our study analysis included total wavefront aberrations.

Also, Zarei-Ghanavati et al showed a rise in high-order aberrations only in 9 patients by Hartmann-Shack aberrometry.¹²

Eccentric fixation may be another possible explanation of the raised ocular aberrations in macular disease¹⁰ which is the concept of Baskaran et al study to prove increased HO aberrations in macular atrophy patients with off-axis vision.²¹

In the current study, we evaluated the optical quality including lower and higher-order aberrations. There wasn't a significant difference between the two groups in terms of lower and higher-order aberrations such as trefoil, coma, total HO, total LO, defocus, PSF, MTF, and total RMS.

Visual acuity in the CSCR group was significantly lower than the fellow eye. Astigmatism and spherical equivalent were not significantly different between groups. Significant UCDVA decrease without acceptable changes in the spherical equivalent of refractive errors and other aberrations suggests that more factors, for example, axial length difference had an impact on it. It may also be rationalized by the acute process of CSCR.

This study had several limitations. The sample size was small, and all of our patients were acute CSC, therefore chronic CSCR phase details and also treatment consequences were not evaluated. We recommend future studies with larger number of patients, including acute

and chronic CSC and other types of macular diseases and deviding total aberrations to internal and corneal wavefront aberrations.

Conclusion

Central serous chorioretinopathy (CSCR) is a condition of choroidal and retinal pathologies that may affect vision. To easily understand vison features of CSCR patients we used objective materials of OCT and I Trace parameters, and we concluded that although CSCR reduced uncorrected visual acuity, it did not change total low and high order aberrations such as trefoil, coma, total HO, total LO, defocus, PSE, MTF, and total RMS while mean sub-foveal fluid height was even more than the half of central foveal thickness.

Conflict of Interest

The authors declare no competing interests.

Ethical Approval

The study protocol had approval by the institutional review board and the clinical research ethics committee of Tabriz University of medical sciences. It entirely was conducted in compliance with the Declaration of Helsinki. All cases had informed consent for participation in the study.

Author's Contributions

BKG: Collected the data, Conceived and designed the analysis, wrote the paper
 NT: Collected the data, contributed data or analysis tools, performed the analysis
 MRN: Conceived and designed the analysis, performed the analysis, wrote the paper

Acknowledgements

We thank patients who have contributed to this work.

Study Highlights

What is current knowledge?

- Retinal disorders affect visual acuity and visual quality including wavefront aberrations.

What is new here?

- CSCR type of retinal involvement does not lead to total wavefront aberrations changes.

Funding

None.

References

1. Kang S, Park YG, Kim JR, Seifert E, Theisen-Kunde D, Brinkmann R, et al. Selective retina therapy in patients with chronic central serous chorioretinopathy: a pilot study. *Medicine (Baltimore)*. 2016;95(3):e2524. doi: 10.1097/md.0000000000002524.
2. Zayit-Soudry S, Moroz I, Loewenstein A. Retinal pigment epithelial detachment. *Surv Ophthalmol*. 2007;52(3):227-43. doi: 10.1016/j.survophthal.2007.02.008.
3. Liew G, Quin G, Gillies M, Fraser-Bell S. Central serous chorioretinopathy: a review of epidemiology and pathophysiology. *Clin Exp Ophthalmol*. 2013;41(2):201-14. doi: 10.1111/j.1442-9071.2012.02848.x.
4. Kitzmann AS, Pulido JS, Diehl NN, Hodge DO, Burke JP. The incidence of central serous chorioretinopathy in Olmsted county, Minnesota, 1980-2002. *Ophthalmology*. 2008;115(1):169-73. doi: 10.1016/j.ophtha.2007.02.032.
5. Wang M, Sander B, la Cour M, Larsen M. Clinical characteristics of subretinal deposits in central serous chorioretinopathy. *Acta Ophthalmol Scand*. 2005;83(6):691-6. doi: 10.1111/j.1600-0420.2005.00582.x.
6. Riordan-Eva P, Whitcher J, Vaughan-Whitehead D, Asbury T. Vaughan & Asbury's General Ophthalmology. Univerza v Ljubljani, Medicinska fakulteta; 2011.
7. Prieto PM, Vargas-Martín F, Goelz S, Artal P. Analysis of the performance of the Hartmann-Shack sensor in the human eye. *J Opt Soc Am A Opt Image Sci Vis*. 2000;17(8):1388-98. doi: 10.1364/josaa.17.001388.
8. Marsack JD, Thibos LN, Applegate RA. Metrics of optical quality derived from wave aberrations predict visual performance. *J Vis*. 2004;4(4):8. doi: 10.1167/4.4.8.
9. Wakil JS, Padrick TD, Molebny S. The iTrace combination corneal topography and wavefront system by Tracey technologies. In: *Corneal topography in the wavefront era*. SLACK Inc; 2006. p. 177-88.
10. Miháltz K, Kovács I, Weingessel B, Vecsei-Marlovits PV. Ocular Wavefront aberrations and optical quality in diabetic macular edema. *Retina*. 2016;36(1):28-36. doi: 10.1097/iae.0000000000000646.
11. Bessho K, Bartsch DU, Gomez L, Cheng L, Koh HJ, Freeman WR. Ocular wavefront aberrations in patients with macular diseases. *Retina*. 2009;29(9):1356-63. doi: 10.1097/IAE.0b013e3181a5e657.
12. Zarei-Ghanavati S, Banaee T, Abrishami M, Dehghani A. Macular disease affects the outcome of ZyWave™ aberrometry. *Ophthalmic Surg Lasers Imaging Retina*. 2011;42(1):26-30. doi: 10.3928/15428877-20101124-08.
13. Sánchez-Tocino H, Alvarez-Vidal A, Maldonado MJ, Moreno-Montañés J, García-Layana A. Retinal thickness study with optical coherence tomography in patients with diabetes. *Invest Ophthalmol Vis Sci*. 2002;43(5):1588-94.
14. Jun I, Choi YJ, Kim EK, Seo KY, Kim TI. Internal spherical aberration by ray tracing-type aberrometry in multifocal pseudophakic eyes. *Eye (Lond)*. 2012;26(9):1243-8. doi: 10.1038/eye.2012.129.
15. Visser N, Berendschot TT, Verbakel F, Tan AN, de Brabander J, Nuijts RM. Evaluation of the comparability and repeatability of four wavefront aberrometers. *Invest Ophthalmol Vis Sci*. 2011;52(3):1302-11. doi: 10.1167/iops.10-5841.
16. Lombardo M, Lombardo G. Wave aberration of human eyes and new descriptors of image optical quality and visual performance. *J Cataract Refract Surg*. 2010;36(2):313-31. doi: 10.1016/j.jcrs.2009.09.026.
17. Miháltz K, Kovács I, Kránitz K, Erdei G, Németh J, Nagy ZZ. Mechanism of aberration balance and the effect on retinal image quality in keratoconus: optical and visual characteristics of keratoconus. *J Cataract Refract Surg*. 2011;37(5):914-22. doi: 10.1016/j.jcrs.2010.12.040.
18. Dai GM. *Wavefront Optics for Vision Correction*. SPIE Press; 2008.
19. Vinciguerra P, Camesasca FI. *Refractive Surface Ablation: PRK, LASEK, Epi-LASIK, Custom, PTK, and Retreatment*. Slack Incorporated; 2007.
20. Lee K, Sohn J, Choi JG, Chung SK. Optical quality in central serous chorioretinopathy. *Invest Ophthalmol Vis Sci*. 2014;55(12):8598-603. doi: 10.1167/iops.14-14679.
21. Baskaran K, Rosén R, Lewis P, Unsbo P, Gustafsson J. Benefit of adaptive optics aberration correction at preferred retinal locus. *Optom Vis Sci*. 2012;89(9):1417-23. doi: 10.1097/OPX.0b013e318264f2a7.