



A Rare Case Presentation of Adenoid Cystic Carcinoma of the Breast in a 36-Year-Old Fe-male

Aradhana Mohan ^{a++}, Geeta S Narayanan ^{a#}
and Kiran Kumar BR ^{a†*}

^a Department of Radiation Oncology, Vydehi Institute of Medical Sciences and Research Centre, Karnataka, India.

Authors' contributions

This work was carried out in collaboration among all authors. All authors read and approved the final manuscript.

Article Information

DOI: <https://doi.org/10.9734/irjo/2025/v8i1169>

Open Peer Review History:

This journal follows the Advanced Open Peer Review policy. Identity of the Reviewers, Editor(s) and additional Reviewers, peer review comments, different versions of the manuscript, comments of the editors, etc are available here: <https://www.sdiarticle5.com/review-history/129527>

Case Report

Received: 13/11/2024

Accepted: 15/01/2025

Published: 17/01/2025

ABSTRACT

Background: Primary adenoid cystic carcinoma (ACC) of breast is rarely seen clinically. It is a special subtype of triple-negative breast cancer characterized by low expression of Ki-67, low malignant potential, slow progression and favourable prognosis. To date, treatment for this disease is controversial and no consensus is reached. We analyzed clinical manifestations and pathological characteristics of a primary breast ACC and reported in combination with literature review to promote understanding, diagnosis and treatment of this disease.

Case presentation: We reviewed a case of 36-year-old female with pathologically diagnosed breast ACC and treated at our department. Molecular type was triple negative and Ki-67 expression was low (5/7). Patient underwent Modified Radical Mastectomy with Axillary Lymph node

⁺⁺ Junior Resident;

[#] Professor and Head;

[†] Assistant Professor;

^{*}Corresponding author: E-mail: drkiranbr@yahoo.com;

Cite as: Mohan, Aradhana, Geeta S Narayanan, and Kiran Kumar BR. 2025. "A Rare Case Presentation of Adenoid Cystic Carcinoma of the Breast in a 36-Year-Old Fe-Male". *International Research Journal of Oncology* 8 (1):1-7. <https://doi.org/10.9734/irjo/2025/v8i1169>.

Dissection. She received both adjuvant chemotherapy and adjuvant radiation. At the follow-up of 36 months patient was disease free and was on regular follow up.

Conclusion: Breast ACC is accompanied with favourable prognosis, which is different from typical triple-negative breast cancer. Accurate diagnosis of ACC is particularly important. Multidisciplinary approach should be considered in the management.

Keywords: Breast; adenoid cystic carcinoma; treatment, prognosis; chemotherapy; radiotherapy.

1. INTRODUCTION

“Adenoid cystic carcinoma (ACC) of the breast is rare, accounting for less than 0.1% of all breast cancers” (Rosen (1989). “This variant is typically seen in the salivary glands but has been reported in other organs including the breast, skin, lung, cervix, larynx, and Bartholin gland” (Santamaría et al. 1998). “It is made up of a mix of epithelial and myoepithelial neoplastic cells that grow in cribriform, tubular, and/or solid patterns” (Grabenstetter et al. (n.d.). Unlike ACC in the salivary gland, ACC of the breast has a good prognosis, with axillary metastases being rare. Given the rarity of this tumor, diagnosis remains a challenge.

“Mammographically, ACCs have been reported as smooth or irregular masses or asymmetric densities” (Santamaría et al. 1998). “Distant metastases, usually to the lung, can occur without positive axillary nodes, and local recurrences are more likely if radiotherapy was not administered” (Pia-Foschini et al. 2003). “It is a good-prognosis subtype of triple-negative breast cancer (i.e., tumors that are devoid of estrogen receptor, progesterone receptor, and human epidermal growth factor receptor 2 expression, and express basal cell markers) characterized by low expression of Ki-67, low malignant potential, slow progression and favorable prognosis” (Zhang et al. 2022). “Treatment may consist of either lumpectomy with radiotherapy, or mastectomy; with both surgical options associated with equivalent survival” (Boujelbene et al. 2012). “There is no clear evidence on the literature on the efficacy of adjuvant systemic therapy for the treatment of ACC of the breast. The 5-year and 10-year survival rates are greater than 95% and 90%, respectively, and lymph node metastasis, as well as distant metastases, which primarily affect visceral organs, are uncommon” (Liu et al. 2022, Hatwar et al. 2021, Lafkihq et al. (2021).

Hence, we report this rare variant of Breast Cancer in a 36-year-old female who presented to our oncology department.

2. CASE PRESENTATION

A 36-year-old female with no personal or family history of breast cancer, presented to our department with complaints of palpable non-painful lump in the lower quadrant of left breast. The patient has past history of benign breast disease in left breast 2 years back and underwent lump excision. the biopsy showed features favoring lymphocytic maculopathy.

She was evaluated and diagnosed as a case of carcinoma of left breast cT3N0M0. Bilateral ultrasonomammogram showed ill-defined irregular hypoechoic lesion taller than wide measuring 3.3 x 3 cm angular margins retro areolar region of left breast 5- 8 o clock region. The lesion shows internal vascularity. No evidence of calcification. Another few hypoechoic lesion are seen adjacent to the lesion measuring 5 mm. Left axilla shows few benign lymph nodes largest measuring 14 x 9 mm. BIRADS (Breast imaging reporting and data system) scoring was found to be 4. A true cut biopsy was taken which was suggestive of Adenoid Cystic Carcinoma.

She underwent Modified radical mastectomy of left breast with axillary lymph node dissection. Post-operative period was uneventful. On Post-Operative Histopathological examination:

Microscopically, tumor shows an invasive neoplasm composed of basaloid cells with scanty cytoplasm, with high nuclear to cytoplasmic ratio and mild pleomorphism. The tumor cells are seen invading in solid nests, in a desmoplastic and myxoid stroma, Mitosis are few. Cribriform pattern with luminal basement membrane like material noted in some foci. Lymphovascular and perineural invasion noted.15 Axillary lymph nodes were dissected and are free of tumor. Her pathological staging was pT3N0Mx. Photomicrograph of histopathologic specimen shows cribriform architecture (Fig. 1).

Immunohistochemistry (IHC) demonstrated diffuse expression of cytokeratin 7 (CK7). The tumor lacked estrogen receptor (ER),

progesterone receptor (PR) and human epidermal growth factor receptor-2 (HER2) expression. The Ki67 proliferation index was approximately 10%. A medical oncology consultation was obtained. Given the triple negative phenotype and biopsy proven negative

lymph node status, adjuvant chemotherapy was recommended. Patient was given Dose dense Adriamycin, Cyclophosphamide (AC) for four cycles and Paclitaxel for four cycles, which she tolerated well.

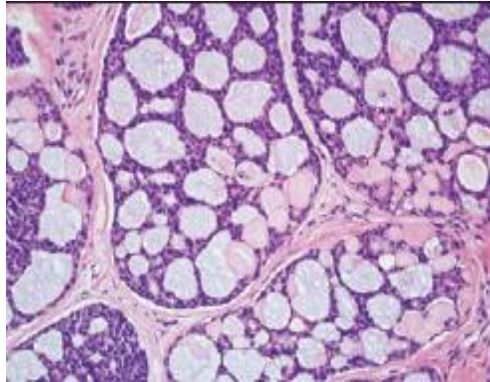


Fig. 1. Photomicrograph of histopathologic specimen shows cribriform architecture, with predominantly glandular spaces with basophilic secretions and focal cylindromatous nodules.

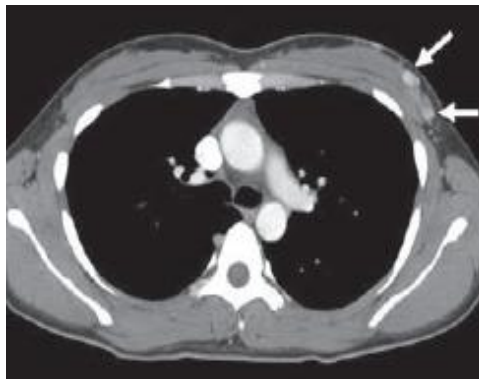

Fig. 2. Contrast-enhanced CT image of chest shows nodular areas (arrows) of rapid contrast enhancement in left breast, corresponding to ACC.

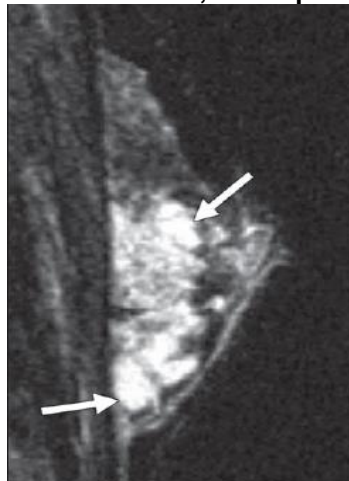

Fig. 3. Fat-saturated, sagittal, T2-weighted MR image of left breast shows areas of hyperintense T2 signal within mass (arrows)

The patient was referred to radiation oncology and adjuvant radiation was planned in view of large tumor size and advanced disease. She received adjuvant radiation therapy to 40 Gray in 15 fractions to left chest wall by 3DCRT (3-Dimensional Conformal Radiation Therapy). She tolerated the treatment well. She was on regular 3 monthly follow-up. She has remained clinically disease free at one year follow up.

3. DISCUSSION

“ACC accounts for only 0.1% to 1% of all breast tumors” (Alis et al. 2008). “There have been case reports on ACC in salivary glands, digestive tract, external auditory canal, skin, uterus, and breast cancer (Bell and Hanna 2013), Dillon et al. 2016). Breast ACC mostly affects women in their fifth and sixth decades of life” (Gordillo 2021). “Breast ACC can occur in men even though it is primarily seen in females” (Coates et al. 2010).

“ACC is most commonly found in the superior lateral quadrant or beneath the areola of the breast. The most common chief complaints are palpable masses” (Alis et al. 2008, Parisi et al. 2021). “The mass is often solitary, and reports of multiple masses are rare. On palpation, tender is seen if tumor is located adjacent to the peripheral neural network. Rarely it can involve nipple and breast skin retractions, as well as pectoralis muscle invasion. For early detection fine needle biopsy plays an important role” (Huang et al. 2018, Blanco et al. 2005).

“There is no significant specificity in the imaging presentation of primary breast ACC based on imaging of previous cases. It has been reported that the X-ray appearance of breast ACC can be irregular and high-density mass with fuzzy edge, containing slightly low-density or lipid density lesions, with less calcification. Ultrasound appearance of breast ACC is non-mass like lesion with high echo and no distribution along direction of catheters. Likewise, there are some valuable findings on MRI. Most lesions of breast ACC are clear. On T2WI, large breast ACC can show extensive internal septum of high and low signal, which can be enhanced in delayed phase” (Tang et al. 2015, Glazebrook et al. 2010). “Therefore, Katrina et al. concluded that combination of multiple imaging examinations could increase diagnostic efficiency, despite final diagnosis still depended on pathology” (Bhutani et al. 2018).

“MYB is the first discovered proto-oncogene located in 6q22-23, which has strong

carcinogenic effect and is known to be expressed in a variety of malignant tumours. Nuclear factor IB (NFIB) is a member of the NFI family and serves as a protein coding gene located in 9p23-24. It plays an important role in cell proliferation, apoptosis and development. ACC repetitive translocation t (6; 9) (q22-23; p23-24) leads to the fusion of MYB and NFIB, which is the main molecular mechanism of the disease. A large number of studies have shown that the fusion of MYB and NFIB is closely related to the occurrence and development of breast ACC” (Brill et al. 2011), Martelotto et al. 2015).

“The pathological grading of ACC is disputed. According to the cell structure, tumours composed of tubular or cribriform structures alone are classified into histological grade I; those with solid component < 30% are classified into histological grade II and those with solid component ≥ 30% are classified into histological grade III. The higher the percentage of solid components, the worse the prognosis of the patients” (Bhutani et al. (2018). “There is also another classification system: classic ACC is classified into low grade and solid adenoid cystic carcinoma with basal cell like features is classified into high grade” (Foschini et al. 2016).

“Surgery is now recognized as the primary treatment for breast ACC patients. However, due to the rarity of this pathological type, there is no clear guidance in the selection of detailed surgical method for this disease, resulting in differences in treatment. Ro et al. suggested that the operation method should be selected according to the ACC grade. Tumour lumpectomy should be used for grade I tumours, mastectomy should be used for grade II tumours, and mastectomy plus lymph node dissection should be used for grade III tumours” (Ro et al. 1987). “The axillary lymph node metastasis of classic breast ACC is rare, generally 0–2%. Axillary lymph node dissection (ALND) is not necessary if there is no preoperative definite clinical evidence of axillary lymph node metastasis. Thompson et al. investigated 244 patients with confirmed breast ACC, discovering that patients with unknown lymph node status have the same favourable 10-year relative cumulative survival rate as known non-lymph node metastasis patients. Therefore, the author believed that ALND was not necessary for patients with breast ACC, especially for patients with T1 stage” (Thompson et al. 2011). “Kulkarni et al. designed a clinical study and included 933 patients with breast ACC, among whom 6%

received axillary lymph node assessment and only 5% were axillary lymph node positive. He came to the same conclusion that ALND was not necessary for breast ACC patients” (Kulkarni et al. 2013).

There are literatures on postoperative adjuvant RT, showing that postoperative adjuvant RT can improve the overall survival (OS) and disease-specific survival of patients after receiving local surgery (Coates et al. 2010). Khanfir et al. retrospectively analysed 61 breast ACC patients undergoing BCS. The result indicated that 5-year local area control rate of patients with adjuvant RT was higher than those without RT. The author suggested that BCS should be the preferred treatment for patients with breast ACC and adjuvant RT could bring more benefits to patients (Khanfir et al. 2012).

“At present, there are still controversies about adjuvant CT after operation and no consensus is reached. Arpino G et al. suggested that postoperative adjuvant CT did not improve disease free survival or OS in breast cancer patients (Arpino et al. 2002). Treitl et al. investigated six patients with breast ACC, and none of them were found accompanied with lymph node metastasis. The researcher assumed that patients with breast ACC did not need adjuvant CT after operation” (Treitl et al. 2018). “Coincidentally, there is another study in which only 11.3% of all patients receive adjuvant CT after surgery. However, for patients with axillary lymph node metastasis, some experts claim that systematic adjuvant CT is necessary and for patients with high grade or large tumour with diameter larger than 3 cm, adjuvant CT should be considered” (Treitl et al. (2018).

“ACC of breast is often regarded as a subtype of TNBC. Therefore, endocrine therapy is unnecessary. Yigit retrospectively reviewed seven patients diagnosed with breast ACC. IHC showed that expression of progesterone receptor (PR) and HER2 was absent in all patients. Only one patient showed weak positive expression of estrogen receptor (ER). Besides, six of them showed positive expression of androgen receptor. Therefore, the author presented that hormone therapy could be applied in androgen receptor positive patients in the future” (Boujelbene et al. 2012). However, more in-depth studies are needed to confirm this viewpoint.

4. CONCLUSION

Breast ACC differs from traditional TNBC. It is characterized by slower clinical process and lower invasiveness. It is necessary to diagnosis breast ACC clearly. At present, BCS and mastectomy are widely used and ALND is evitable. Adjuvant RT should be considered in Locally advanced and also in patients undergoing BCS. Regular review and long-term follow- up for patients are absolutely necessary.

DISCLAIMER (ARTIFICIAL INTELLIGENCE)

Author(s) hereby declare that NO generative AI technologies such as Large Language Models (ChatGPT, COPILOT, etc) and text-to-image generators have been used during writing or editing of this manuscript.

CONSENT

As per international standards or university standards, patient(s) written consent has been collected and preserved by the author(s).

ETHICAL APPROVAL

As per international standards or university standards written ethical approval has been collected and preserved by the author(s).

COMPETING INTERESTS

Authors have declared that no competing interests exist.

REFERENCES

- Alis, H., Yigitbas, H., Kapan, S., Kalayci, M., Kilic, G., & Aygun, E. (2008). Multifocal adenoid cystic carcinoma of the breast: An unusual presentation. *U.S. National Library of Medicine*.
- Alis, H., Yigitbas, H., Kapan, S., Kalayci, M., Kilic, G., & Aygun, E. (2008). Multifocal adenoid cystic carcinoma of the breast: An unusual presentation. *Can J Surg*, 51(2), E36–E37.
- Arpino, G., Clark, G. M., Mohsin, S., Bardou, V. J., & Elledge, R. M. (2002). Adenoid cystic carcinoma of the breast: Molecular markers, treatment, and clinical outcome. *Cancer*, 94(8), 2119–2127.
- Bell, D., & Hanna, E. Y. (2013). Head and neck adenoid cystic carcinoma: What is new in

- biological markers and treatment? *Curr Opin Otolaryngol Head Neck Surg*, 21(2), 124–129.
- Bhutani, N., Kajal, P., & Singla, S. (2018). Adenoid cystic carcinoma of the breast: Experience at a tertiary care centre of Northern India. *Int J Surg Case Rep*, 51, 204–209.
- Bhutani, N., Kajal, P., & Singla, S. (2018). Adenoid cystic carcinoma of the breast: Experience at a tertiary care centre of Northern India. *Int J Surg Case Rep*, 51, 204–209.
- Blanco, M., Egozi, L., Lubin, D., & Poppiti, R. (2005). Adenoid cystic carcinoma arising in a fibroadenoma. *Ann Diagn Pathol*, 9(3), 157–159.
- Boujelbene, N., Khabir, A., Boujelbene, N., Jeanneret Sozzi, W., Mirimanoff, R. O., & Khanfir, K. (2012). Clinical review–breast adenoid cystic carcinoma. *Breast*, 21(2), 124–127.
- Boujelbene, N., Khabir, A., Jeanneret Sozzi, W., Mirimanoff, R. O., & Khanfir, K. (2012). Clinical review–breast adenoid cystic carcinoma. *Breast*, 21(2), 124–127.
- Brill, L. B. 2nd, Kanner, W. A., Fehr, A., Andren, Y., Moskaluk, C. A., Loning, T., Stenman, G., & Frierson, H. F. Jr. (2011). Analysis of MYB expression and MYB-NFIB gene fusions in adenoid cystic carcinoma and other salivary neoplasms. *Mod Pathol*, 24(9), 1169–1176.
- Coates, J. M., Martinez, S. R., Bold, R. J., & Chen, S. L. (2010). Adjuvant radiation therapy is associated with improved survival for adenoid cystic carcinoma of the breast. *J Surg Oncol*, 102(4), 342–347.
- Coates, J. M., Martinez, S. R., Bold, R. J., & Chen, S. L. (2010). Adjuvant radiation therapy is associated with improved survival for adenoid cystic carcinoma of the breast. *J Surg Oncol*, 102(4), 342–347.
- Dillon, P. M., Chakraborty, S., Moskaluk, C. A., Joshi, P. J., & Thomas, C. Y. (2016). Adenoid cystic carcinoma: A review of recent advances, molecular targets, and clinical trials. *Head Neck*, 38(4), 620–627.
- Foschini, M. P., Rizzo, A., De Leo, A., Laurino, L., Sironi, M., & Rucco, V. (2016). Solid variant of adenoid cystic carcinoma of the breast: A case series with proposal of a new grading system. *Int J Surg Pathol*, 24(2), 97–102.
- Glazebrook, K. N., Reynolds, C., Smith, R. L., Gimenez, E. I., & Boughey, J. C. (2010). Adenoid cystic carcinoma of the breast. *AJR Am J Roentgenol*, 194(5), 1391–1396.
- Gordillo, C. (2021). Adenoid cystic carcinoma: A case of rare breast cancer. *Elsevier*.
- Grabenstetter, A., Brogi, E., Zhang, H., Razavi, P., Reis-Filho, J. S., VanZee, K. J., et al. (n.d.). Solid-basaloid variant of adenoid cystic carcinoma of the breast with near complete response to neo-adjuvant chemotherapy.
- Hatwar, G., Sharma, R., Wanjari, M., Wankhede, P., Alwadkar, S., & Rodge, H. (2021). A case of mucinous cystadenoma carcinoma. *Journal of Pharmaceutical Research International*, 33(52A), 148–152.
- Huang, M., Jiang, T., Zhao, Q., You, Q., Tian, G., & Wang, B. (2018). Breast adenoid cystic carcinoma: Report of a case with emphasis on routine sonographic findings and shear wave elastography. *J Med Ultrason*, 45(1), 181–184.
- Khanfir, K., Kallel, A., Villette, S., Belkacemi, Y., Vautravers, C., Nguyen, T., Miller, R., Li, Y. X., Taghian, A. G., Boersma, L., et al. (2012). Management of adenoid cystic carcinoma of the breast: A Rare Cancer Network study. *Int J Radiat Oncol Biol Phys*, 82(5), 2118–2124.
- Kulkarni, N., Pezzi, C. M., Greif, J. M., Klimberg, V. S., Bailey, L., Korourian, S., Zuraek, M. (2013). Rare breast cancer: 933 adenoid cystic carcinomas from the National Cancer Data Base. *Ann Surg Oncol*, 20(7), 2236–2241.
- Lafkihq, O., El Jai, S. R., Erguibi, D., Boufettal, R., & Chihab, F. (2021). Retroperitoneal primary cystic tumours: Case series of seven patients and literature review. *Asian Journal of Medicine and Health*, 19(4), 10–15.
<https://doi.org/10.9734/ajmah/2021/v19i430317>
- Liu, Z., Wang, M., Wang, Y., Shen, X., & Li, C. (2022). Diagnosis of adenoid cystic carcinoma in the breast: A case report and literature review. *Termedia Publishing House*.
- Martelotto, L. G., De Filippo, M. R., Ng, C. K., Natrajan, R., Fuhrmann, L., Cyrta, J., Piscuoglio, S., Wen, H. C., Lim, R. S., Shen, R., et al. (2015). Genomic landscape of adenoid cystic carcinoma of the breast. *J Pathol*, 237(2), 179–189.
- Parisi, S., Ruggiero, R., Gualtieri, G., Volpe, M. L., Rinaldi, S., Nesta, G., Bogdanovich, L., Lucido, F. S., Tolone, S., Parmeggiani, D.,

- et al. (2021). Combined LOCalizer and intraoperative ultrasound localization: First experience in localization of non-palpable breast cancer. *In Vivo*, 35(3), 1669–1676.
- Pia-Foschini, M., Reis-Filho, J. S., Eusebi, V., & Lakhani, S. R. (2003). Salivary gland-like tumours of the breast: Surgical and molecular pathology. *J Clin Pathol*, 56, 497–506.
- Ro, J. Y., Silva, E. G., & Gallager, H. S. (1987). Adenoid cystic carcinoma of the breast. *Hum Pathol*, 18(12), 1276–1281.
- Rosen, P. P. (1989). Adenoid cystic carcinoma of the breast: A morphologically heterogeneous neoplasm. *Pathol Annu*, 24, 237–254.
- Santamaría, G., Velasco, M., Zanón, G., et al. (1998). Adenoid cystic carcinoma of the breast: Mammographic appearance and pathologic correlation. *AJR*, 171, 1679–1683.
- Santamaría, G., Velasco, M., Zanón, G., et al. (1998). Adenoid cystic carcinoma of the breast: Mammographic appearance and pathologic correlation. *AJR*, 171, 1679–1683.
- Tang, W., Peng, W. J., Gu, Y. J., Zhu, H., Jiang, T. T., & Li, C. (2015). Imaging manifestation of adenoid cystic carcinoma of the breast. *J Comput Assist Tomogr*, 39(4), 523–530.
- Thompson, K., Grabowski, J., Saltzstein, S. L., Sadler, G. R., & Blair, S. L. (2011). Adenoid cystic breast carcinoma: Is axillary staging necessary in all cases? Results from the California Cancer Registry. *Breast J*, 17(5), 485–489.
- Treitl, D., Radkani, P., Rizer, M., El Hussein, S., Paramo, J. C., & Mesko, T. W. (2018). Adenoid cystic carcinoma of the breast, 20 years of experience in a single center with review of literature. *Breast Cancer*, 25(1), 28–33.
- Zhang, M., Liu, Y., Yang, H., Jin, F., & Zheng, A. (2022). Breast adenoid cystic carcinoma: A report of seven cases and literature review. *BMC Surgery*. BioMed Central.

Disclaimer/Publisher's Note: The statements, opinions and data contained in all publications are solely those of the individual author(s) and contributor(s) and not of the publisher and/or the editor(s). This publisher and/or the editor(s) disclaim responsibility for any injury to people or property resulting from any ideas, methods, instructions or products referred to in the content.

© Copyright (2025): Author(s). The licensee is the journal publisher. This is an Open Access article distributed under the terms of the Creative Commons Attribution License (<http://creativecommons.org/licenses/by/4.0>), which permits unrestricted use, distribution, and reproduction in any medium, provided the original work is properly cited.

Peer-review history:
The peer review history for this paper can be accessed here:
<https://www.sdiarticle5.com/review-history/129527>